



# Open Medicine Journal

Content list available at: <https://openmedicinejournal.com>



CrossMark

## CASE REPORT

# Systemic Lupus Erythematosus in a Patient with Liver Cirrhosis: Case Report and Literature Review

Yangyang Hu<sup>1,\*</sup> and Shaoxian Hu<sup>1</sup>

<sup>1</sup>Department of Rheumatology and Immunology, Tongji Hospital, Tongji Medical College, Huazhong University of Science and Technology, Wuhan, China

### Abstract:

#### Background:

There are no treatment guidelines for systemic lupus erythematosus (SLE) for the patients with decompensated cirrhosis, especially for those who have a history of hepatitis B virus (HBV) infection, gastrointestinal bleeding and gastric fundus ulceration.

#### Case Presentation:

A 50-year-old woman who had a six-year history of lupus was admitted to our hospital. One month prior, at the Department of Gastroenterology, she was diagnosed with decompensated liver cirrhosis with gastric fundal varicose bleeding, and HBV-related infection. During her visit to the hospital, gastroscopy showed esophageal varices and a large gastric fundus ulcer. Laboratory data indicated the rapid decrease of red blood cells, granulocytes and platelets and the persistent increase of serum globulin levels. According to the patient's medical history and existing laboratory examination, the patient experienced an exacerbation of SLE, which could be life-threatening. While it remained uncertain whether the liver cirrhosis was caused by SLE or the HBV infection, immediate treatment was necessary. Consequently, she was treated with a low dose of methylprednisolone and mycophenolate mofetil (MMF). The treatment resulted in significant clinical improvement. Moreover, there was no indication of HBV reactivation, gastrointestinal bleeding, liver dysfunction or other drug-induced side effects.

#### Conclusion:

This case indicated that irrespective of the underlying causes of liver cirrhosis, the combination of a low dose of methylprednisolone and MMF is an effective treatment method to inhibit the disease process for patients with SLE and decompensated liver cirrhosis, a large gastric fundus ulcer and HBV infection.

**Keywords:** Systemic lupus erythematosus, Liver cirrhosis, Hepatitis B virus, Gastrointestinal bleeding, Methylprednisolone, Mycophenolate mofetil.

### Article History

Received: October 19, 2022

Revised: May 30, 2023

Accepted: June 06, 2023

## 1. INTRODUCTION

Systemic lupus erythematosus (SLE) is a chronic autoimmune disease that damages multiple systems and has a variety of clinical presentations, such as leukopenia, renal failure, antiphospholipid syndrome and thrombocytopenia. Glucocorticoids (GCs) and immunosuppressive medications are the traditional treatments to induce disease remission in patients with lupus. However, numerous challenges still need to be resolved, such as cirrhosis or gastrointestinal bleeding in SLE patients. Cirrhosis is classified as compensated or decompensated depending on the absence or presence of

ascites, encephalopathy, variceal bleeding or jaundice. The prognosis of patients with decompensated cirrhosis is usually very poor, with an estimated 5-year survival rate of 14%–35%. The administration of GCs or immunosuppressive medications to patients with cirrhosis may cause gastrointestinal bleeding, liver dysfunction and other adverse reactions. One controversial question that remains is how to treat the SLE patient with decompensated liver cirrhosis. Here, we report a patient who was diagnosed SLE during the clinical course of decompensated liver cirrhosis with hepatitis B virus (HBV) infection, and a good therapeutic effect was achieved using low-dose methylprednisolone and mycophenolate mofetil (MMF).

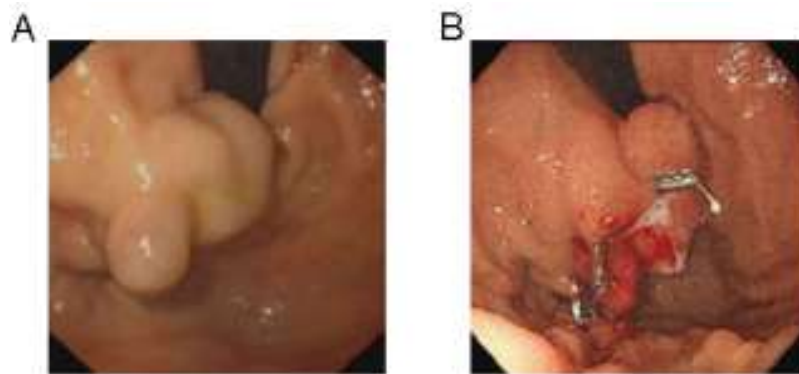
\* Address correspondence to this author at the Department of Rheumatology and Immunology, Tongji Hospital, Tongji Medical College, Huazhong University of Science and Technology, Wuhan, China; E-mail: [rh\\_sxhu@126.com](mailto:rh_sxhu@126.com)

## 2. CASE PRESENTATION

A 50-year-old woman was admitted to the Department of Rheumatology and Immunology in our hospital. This patient was diagnosed with SLE when she was 44 years old, but since then, she has not gone to the hospital regularly to receive treatment.

One month prior to her visit to the Department of Gastroenterology, the patient presented with melena and was diagnosed with liver cirrhosis with HBV infection and gastric fundal varicose bleeding. Endoscopy revealed one large isolated fundal gastric varix (Fig. 1A). She underwent endoscopic ultrasound (EUS)-guided coil embolization and

absorbable gelatin sponge injection to manage the isolated fundal gastric variceal bleeding (Fig. 1B). The patient was managed concurrently with entecavir. Melena did not reappear after these treatments. Before the patient was discharged from the hospital, a routine examination revealed the following blood parameters: white blood cells (WBC):  $3.63 \times 10^9/L$  (normal range:  $3.5-9.5 \times 10^9/L$ ), hemoglobin (HB): 94 g/L (normal range: 115.0–150.0 g/L) and platelets (PLT):  $114 \times 10^9/L$  (normal range:  $125.0-350.0 \times 10^9/L$ ). Because the patient was positive for antinuclear antibody (ANA) and anti-double stranded DNA (anti-dsDNA), she was informed to follow up with the Department of Rheumatology and Immunology.



**Fig. (1).** The endoscopy image showed large isolated fundal gastric varices before and after treatment. (A). Endosonographic image of the large isolated fundal gastric varices prior to endoscopic ultrasound (EUS)-guided coil embolization and absorbable gelatin sponge injection. (B). Endosonographic image after EUS-guided embolization and absorbable gelatin sponge injection.

**Table 1. Laboratory results on admission.**

Laboratory Parameters	Result	Reference Range
White blood cells	$3.18 \times 10^9/L$	$3.50-9.50 \times 10^9/L$
Haemoglobin	84 g/L	115.0-150.0g/L
Platelets	$54 \times 10^9/L$	$125.0-350.0 \times 10^9/L$
MCV	91.2 fL	82.0-100.0 fL
APTT	38.6 s	29.0-42.0 s
PT	13.9 s	11.5-14.5 s
D-dimer	2.29 $\mu\text{g/ml}$	<0.5 $\mu\text{g/ml}$
Fibrinogen	2.47 g/L	2.00-4.00 g/L
AST	29 U/L	$\leq 33$ U/L
ALT	7 U/L	$\leq 32$ U/L
ALP	119 U/L	35-105 U/L
$\gamma$ -GT	32 U/L	6-42 U/L
Total protein	73.5 g/L	64-83 g/L
Albumin	27.0 g/L	35-52 g/L
Globin	46.5 g/L	20-35 g/L
Total bilirubin	13.7 $\mu\text{mol/L}$	$\leq 21$ $\mu\text{mol/L}$
Creatinine	48 $\mu\text{mol/L}$	45-84 $\mu\text{mol/L}$
Blood urea nitrogen	1.16 mmol/L	3.38 mmol/L
Sodium	140.9 mmol/L	136-145 mmol/L
Potassium	3.68 mmol/L	3.5-5.1 mmol/L
HBs antigen	0.09 IU/ml	< 0.05 IU/ml
HBs antibody	6.89 MIU/ml	<10 MIU/ml

(Table 1) contd.....

Laboratory Parameters	Result	Reference Range
HBe antibody	0.14 S/CO	>1.0 OS/CO
HBe antigen	0.35 OS/CO	<1.0 OS/CO
HBc antibody	6.62 OS/CO	<1.0 OS/CO
Anti-HCV antibody	0.12 OS/CO	<1.0 OS/CO
HBV-DNA	<1.0×10 <sup>2</sup> IU/ml	Non-reactive

**Abbreviations:** MCV, mean corpuscular volume; PT, prothrombin time; APTT, activated partial thromboplastin time; Anti-HCV antibody, anti-Hepatitis C antibody; HBV-DNA, hepatitis B virus DNA; AST, aspartate aminotransferase; ALT, alanine aminotransferase; APL, alkaline phosphatase;  $\gamma$ -GT,  $\gamma$ -glutamyltransferase.

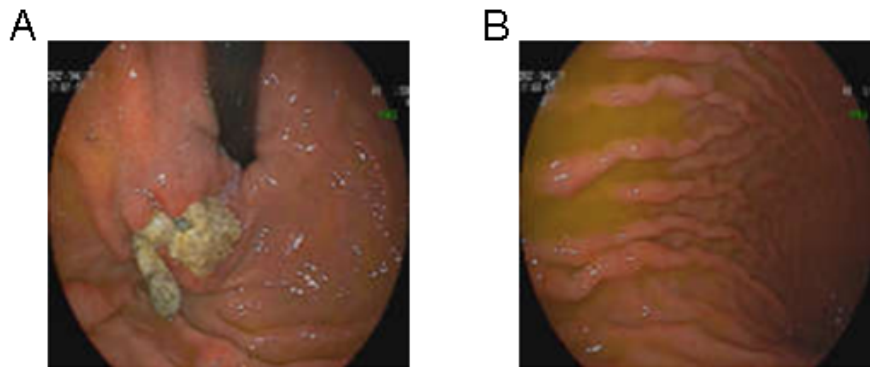
**Table 2. Autoantibody profile.**

Laboratory Parameters	Result	Reference Range
CRP	3.27 mg/L	0-5 mg/L
ESR	34 mm/h	0-20 mm/h
IgG	30.89 g/L	7-16 g/L
IgA	4.19 g/L	0.7-4.0 g/L
IgM	0.48 g/L	0.4-2.3 g/L
C3	0.60 g/L	0.8-1.8 g/L
C4	0.15 g/L	0.1-0.4 g/L
Coombs' test	(+++)	(-)
Anti- $\beta$ 2GP1 antibody	(-)	(-)
Anti-phospholipid antibody	(-)	(-)
Lupus anticoagulant	(-)	(-)
ANA	1:1000	<1:100
Anti-dsDNA antibody	1.97 RU/ml	0-10 RU/ml
Anti-Sm antibody	41.39 RU/ml	0-20 RU/ml
Anti-Ro-52 antibody	>400.00 RU/ml	0-20 RU/ml
Anti-SSA antibody	>400.00 RU/ml	0-20 RU/ml
Anti-SSB antibody	38.87 RU/ml	0-20 RU/ml
Anti-rRNP antibody	<2 RU/ml	0-20 RU/ml
Anti-u1-nRNP antibody	>400.00 RU/ml	RU/ml
Anti-mitochondrial M2 antibody	(-)	(-)
Anti-smooth muscle antibody	(-)	(-)
anti-LKM1 antibody	(-)	(-)
Anti-GP210 antibody	(-)	(-)
Anti-SP100 antibody	(-)	(-)
PR3-ANCA	<0.2AI	<1.0AI
MPO-ANCA	<0.2AI	<1.0AI

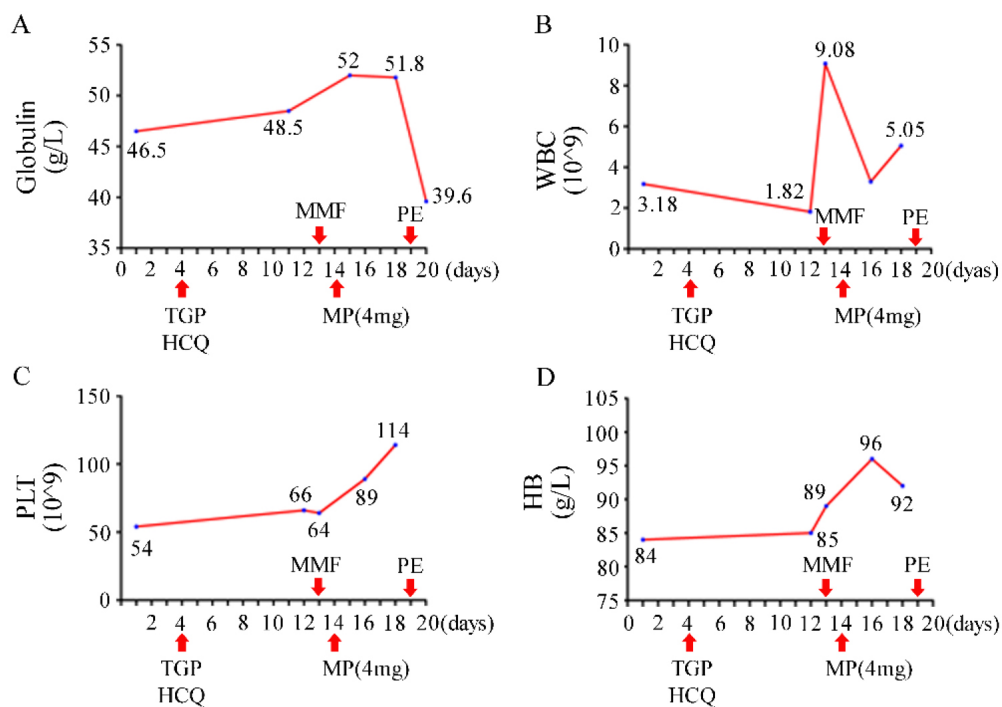
**Abbreviations:** CRP, C-reactive protein; ESR, erythrocyte sedimentation rate; Ig, immunoglobulin; C3, complement 3; C4, complement 4; ANA, antinuclear antibody; PR3-ANCA, proteinase 3-antineutrophil cytoplasmic antibody; MPO-ANCA, myeloperoxidase-antineutrophil cytoplasmic antibody.

Upon the patient's admission to the Department of Rheumatology and Immunology, there was no obvious rash, ulcers, swelling or tenderness of the joints. The laboratory data illustrated in Table 1 showed pancytopenia (WBC  $3.18 \times 10^9/L$ , HB 84 g/L and PLT  $54 \times 10^9/L$ ), which was worse than that of 1 month prior. The serum levels of globulin and albumin were 46.5 g/L and 27 g/L, respectively. Bone marrow aspiration, bone marrow trephine biopsies and electrophoresis of serum proteins did not show any significant abnormalities, ruling out hematological malignancies or hematopoietic dysfunction. Fecal occult blood testing yielded normal results, and urinalysis did not show any signs of proteinuria or occult blood. However, the serum samples showed high levels of ANA, anti-Smith (anti-Sm), anti-U1-ribonucleoprotein (anti-U1-RNP), anti-Sjögren's-syndrome-related antigen A (anti-SSA), anti-Ro52 and anti-Sjögren's syndrome B (anti-SSB)

antibodies. Serum level of complement 3 (C3) was decreased to 0.6 g/L, whereas the level of IgG was increased to 30.89 g/L. The result of the Coombs test was strong positive (+++). Screening for anti-smooth muscle antibody, anti-mitochondrial antibody and anti-liver-kidney microsomal type 1 (LKM1) antibody determined that the serum sample was negative for these antibodies; the autoimmune hepatitis panel was also negative (Table 2). Repeated gastroscopy revealed the presence of gastro-esophageal varices with a large gastric fundus ulcer, which had developed as a result of the earlier coil embolization and absorbable gelatin sponge injection (Fig. 2). Abdominal echography revealed liver cirrhosis and splenomegaly, but no ascites, cholecystitis was observed. The gastroenterologist informed us that splenomegaly could not explain the pancytopenia, and using prednisolone posed a high risk of bleeding due to the gastric fundus ulcer.



**Fig. (2).** The image of repeated endoscopy after a month of treatment is shown. (A). Endoscopic appearance of the large fundal gastric ulcer post EUS-guided coil embolization and injection of gelatin sponge. (B). Gastro-esophageal varices were observed.



**Fig. (3).** Clinical course and trends of globulin (A), WBC (B), PLT (C) and HB (D). WBC, white blood cells; PLT, platelets; HB, haemoglobin; TGP, total glycosides of paeony; HCQ, hydroxychloroquine sulfate; MMF, mycophenolate mofetil; MP, methylprednisolone; PE, plasma exchange.

**Table 3. Laboratory results of outpatient follow-up.**

Laboratory Parameters	Result	Reference Range
White blood cells	4.47×10 <sup>9</sup> /L	3.50-9.50×10 <sup>9</sup> /L
Haemoglobin	92 g/L	115.0-150.0g/L
Platelets	111×10 <sup>9</sup> /L	125.0-350.0×10 <sup>9</sup> /L
MCV	77.3 fL	82.0-100.0 fL
ESR	28 mm/h	0-20 mm/h
AST	15 U/L	≤33 U/L
ALT	30 U/L	≤32 U/L
ALP	89 U/L	35-105 U/L
Y-GT	39 U/L	6-42 U/L
Total protein	76.6 g/L	64-83 g/L

(Table 3) contd.....

Laboratory Parameters	Result	Reference Range
Albumin	35.3 g/L	35-52 g/L
Globin	41.3 g/L	20-35 g/L
Total bilirubin	9.8 $\mu$ mol/L	$\leq$ 21 $\mu$ mol/L
Creatinine	55 $\mu$ mol/L	45-84 $\mu$ mol/L
Blood urea nitrogen	3.17 mmol/L	3.38 mmol/L

**Abbreviations:** MCV, mean corpuscular volume; ESR, erythrocyte sedimentation rate; AST, aspartate aminotransferase; ALT, alanine aminotransferase; APL, alkaline phosphatase; Y-GT, Y-glutamyltransferase.

Treatment with total glycosides of paeony (TGP) and hydroxychloroquine sulfate (HCQ) was started on day 4 of hospitalization. However, despite the treatment, improvements in the patient's leukopenia, anemia, and thrombocytopenia were not observed. The WBC dropped to  $1.82 \times 10^9/L$  two weeks after admission. The serum level of globulin continued to increase unabatedly. The patient refused the therapy of gamma globulin and biologic agents for personal reasons, and oral methylprednisolone tablets at a daily dose of 4 mg and MMF 0.25 g twice daily were added. With the patient's permission, plasma exchange (PE) was performed once. Pancytopenia improved rapidly and serum globulin did not continue to increase significantly (Fig. 3). Upon the patient's discharge from the hospital, instructions were provided to adjust the dosage of MMF to 0.5 g in the morning and 0.25 g in the evening, while continuing the intake of methylprednisolone, HCQ, and entecavir as prescribed previously. At the outpatient visit three months later, the patient's WBC increased to normal and serum globulin returned to 41.3 g/L (Table 3). No side effects of the drugs were evident.

### 3. RESULTS AND DISCUSSION

Based on clinical presentation and laboratory tests, this patient was diagnosed with SLE according to European League against Rheumatic Diseases and American College of Rheumatology criteria in 2019. Hyperglobulinemia and pancytopenia were correlated with disease activity in SLE. She had a history of liver cirrhosis with gastrointestinal bleeding and HBV infection. After admission, the gastroscopy showed oesophageal varices with a large gastric fundus ulcer, which resulted from Child-Pugh B liver cirrhosis. Although the SLE Disease Activity Index 2000 (SLEDAI-2K) score for this patient was 4, the laboratory data indicated an exacerbation of SLE, necessitating urgent treatment. However, it was necessary to choose the type and dosage of medicine carefully because of the risk of drug side effects in this patient.

The treatment of most patients with severe lupus necessitates GCs in combination with immunosuppressive drugs to induce disease remission. However, GC-mediated effects prevent wound repair and induce peptic ulcers (upper gastrointestinal ulcers) in a dose-dependent manner. A retrospective analysis of the incidence of upper gastrointestinal bleeding in patients treated with GCs found that patients with a history of upper gastrointestinal bleeding were more likely to have recurrent gastrointestinal bleeding. One study investigating the dose and duration of prednisone intake by patients with rheumatoid arthritis determined that the frequency of adverse events increased with prednisone dosage, and there was a threshold pattern at 5–7.5 mg/day.

It has been long recognized that immunosuppressive therapy in patients with rheumatic diseases could result in the reactivation of HBV, which is characterized by abnormal liver function, increased levels of serum HBV DNA and hepatic failure. Corticosteroids have been shown to be an independent and additive risk factor for HBV reactivation. The risk was closely related to the dosage and duration of prednisone. The authors identified that a daily dose of prednisolone greater than 5 mg could be a risk factor for HBV reactivation. One prospective cohort study of idiopathic patients with nephrotic syndrome positive for hepatitis B surface antigen (HBs Ag) with 'undetectable' HBV DNA (<1,000 copies/mL) was reported. Compared with the standard prednisone regimen, the combination therapy of MMF and a reduced prednisone dose resulted in better remission rates in idiopathic nephrotic syndrome. The combination-therapy group had lower rates of HBV reactivation. Interestingly, other studies indicated that MMF inhibits the replication of HBV and enhances the anti-HBV effect of entecavir.

Because, to date, there are no guidelines for the treatment of SLE with decompensated cirrhosis, 40% of HBsAg-positive patients who were treated with immunotherapy experience hepatitis flare. Drug-induced liver injury is regarded as the main cause of liver dysfunction in patients with SLE. The disease-modifying antirheumatic drugs (DMARDs) that were most frequently associated with hepatotoxicity were azathioprine and methotrexate. Cyclophosphamide and leflunomide were less frequently associated with hepatotoxicity. The DMARDs, that induced hepatotoxicity rarely, were cyclosporine, hydroxychloroquine, MMF and tacrolimus. MMF, tacrolimus (FK506), and cyclophosphamide were not directly related to fibrosis. There was no optimal choice for the treatment of SLE with cirrhosis among these three drugs.

The cause of the patient's liver cirrhosis was not clear. The present patient had four years of SLE history, and the liver cirrhosis may have been caused by lupus hepatitis (LH) or HBV-related hepatitis. Some experts recognized LH as a subclinical liver dysfunction resulting from SLE. That study found that patients with LH and cirrhosis had a significantly higher rate of thrombocytopenia and leukopenia and a higher level of IgG [13]. The most common feature of LH was mild (< 5  $\times$  ULN, the upper limit of normal range) to moderate (5–10  $\times$  ULN) liver enzyme elevation. Zheng *et al.* reported that there was a 9.3% incidence of LH in 504 SLE patients that were evaluated. It was recommended that LH should be diagnosed by initially ruling out viral hepatitis, alcoholic liver disease and other secondary causes of liver involvement. The liver pathology observed in LH presents as various and nonspecific histological changes, such as non-alcoholic liver

steatosis, lobular inflammation, interface hepatitis, chronic active hepatitis, focal necrosis and nodular regenerative hyperplasia [16, 20, 21]. Complement deposition and vasculitis lead to liver cell necrosis and regeneration, indicating the development of liver cirrhosis [22 - 25]. However, this complication is very rare, and there are no clear recommendations to perform a liver biopsy. In addition to the biochemical abnormalities in liver function, autoantibodies to ribosomal P proteins (anti-rRNP antibodies) are highly specific markers for LH. Several reports have even suggested that LH was caused by these autoantibodies. One international multicenter study indicated that the sensitivity, specificity and diagnostic efficiency of anti-rRNP antibodies were 21.3%, 99.3% and 65.3%, respectively. To date, there is no standardized treatment for LH, although GCs are considered an effective treatment. LH is frequently associated with SLE flares or disease activity, which could return to normal after corticosteroid treatment [17, 26, 30, 31]. One case discussed an LH patient who was refractory not only to corticosteroids but also to immunosuppressants like azathioprine, cyclophosphamide and tacrolimus [32]. However, MMF rapidly controlled the disease activity, despite a reduction in the dose of methylprednisolone.

## CONCLUSION

In summary, we report a patient with a history of decompensated liver cirrhosis, HBV infection and gastric fundal varicose bleeding. Following EUS-guided coil embolization and absorbable gelatin sponge injection, gastroscopy revealed the presence of esophageal varices and a large gastric fundus ulcer during follow-up. The patient, who had a long course of lupus, deteriorated rapidly and was in critical condition. To choose the most appropriate drugs, we had to balance the potential benefits with the possible risks. Finally, the combination of a low dosage of methylprednisolone and MMF proved to be an effective treatment without obvious medical side effects in this present case. Nevertheless, further clinical trials including larger numbers of patients are needed to assess the efficiency and safety of this approach.

## LIST OF ABBREVIATIONS

<b>SLE</b>	= Systemic lupus erythematosus
<b>GC</b>	= Glucocorticoids
<b>HBV</b>	= Hepatitis B virus
<b>MMF</b>	= Methylprednisolone and mycophenolate mofetil
<b>TGP</b>	= Total glycosides of paeony
<b>HCQ</b>	= Hydroxychloroquine sulfate
<b>PE</b>	= Plasma exchange
<b>DMARDs</b>	= Disease-modifying antirheumatic drugs
<b>AST</b>	= Aspartate aminotransferase
<b>ALT</b>	= Alanine aminotransferase
<b>ANA</b>	= Antinuclear antibody
<b>EUS</b>	= Endoscopic ultrasound
<b>LKMI</b>	= Liver-kidney microsomal type 1
<b>HB</b>	= Haemoglobin

## ETHICS APPROVAL AND CONSENT TO PARTICIPATE

Not applicable.

## HUMAN AND ANIMAL RIGHTS

Not applicable.

## CONSENT FOR PUBLICATION

Informed consent was obtained.

## STANDARDS OF REPORTING

CARE guidelines were followed.

## AVAILABILITY OF DATA AND MATERIALS

The datasets used and/or analyzed during the current study are available from the corresponding author (Y.H) on reasonable request.

## FUNDING

This work was supported by the National Science Fund of China (81703058).

## CONFLICTS OF INTEREST

The authors declare no conflict of interest, financial or otherwise.

## ACKNOWLEDGEMENTS

Declared none.

## REFERENCES

- [1] Cojocaru M, Cojocaru IM, Silosi I, Vrabie CD. Manifestations of systemic lupus erythematosus. *Maedica* 2011; 6(4): 330-6. [PMID: 22879850]
- [2] Peng CY, Chien RN, Liaw YF. Hepatitis B virus-related decompensated liver cirrhosis: Benefits of antiviral therapy. *J Hepatol* 2012; 57(2): 442-50. [http://dx.doi.org/10.1016/j.jhep.2012.02.033] [PMID: 22504333]
- [3] Schäcke H, Döcke WD, Asadullah K. Mechanisms involved in the side effects of glucocorticoids. *Pharmacol Ther* 2002; 96(1): 23-43. [http://dx.doi.org/10.1016/S0163-7258(02)00297-8] [PMID: 12441176]
- [4] González-Regueiro JA, Cruz-Contreras M, Merayo-Chalico J, *et al.* Hepatic manifestations in systemic lupus erythematosus. *Lupus* 2020; 29(8): 813-24. [http://dx.doi.org/10.1177/0961203320923398] [PMID: 32390496]
- [5] Fanouriakis A, Kostopoulou M, Alunno A, *et al.* 2019 update of the EULAR recommendations for the management of systemic lupus erythematosus. *Ann Rheum Dis* 2019; 78(6): 736-45. [http://dx.doi.org/10.1136/annrheumdis-2019-215089] [PMID: 30926722]
- [6] Carson JL, Strom BL, Schinnar R, Duff A, Sim E. The low risk of upper gastrointestinal bleeding in patients dispensed corticosteroids. *Am J Med* 1991; 91(3): 223-8. [http://dx.doi.org/10.1016/0002-9343(91)90119-1] [PMID: 1892141]
- [7] Huscher D, Thiele K, Gromnica-Ihle E, *et al.* Dose-related patterns of glucocorticoid-induced side effects. *Ann Rheum Dis* 2009; 68(7): 1119-24. [http://dx.doi.org/10.1136/ard.2008.092163] [PMID: 18684744]
- [8] Reynolds JA, Manch RA, Gish RG. Medical interventions associated with HBV reactivation: Common and less common. *Clin Liver Dis* 2015; 5(2): 32-4. [http://dx.doi.org/10.1002/cld.413] [PMID: 31040944]
- [9] Li X, Tian J, Wu J, *et al.* A comparison of a standard-dose prednisone regimen and mycophenolate mofetil combined with a lower

- prednisone dose in chinese adults with idiopathic nephrotic syndrome who were carriers of hepatitis B surface antigen: A prospective cohort study. *Clin Ther* 2009; 31(4): 741-50.  
[<http://dx.doi.org/10.1016/j.clinthera.2009.04.011>] [PMID: 19446147]
- [10] Gong ZJ, De Meyer S, Clarysse C, *et al.* Mycophenolic acid, an immunosuppressive agent, inhibits HBV replication *in vitro*. *J Viral Hepat* 1999; 6(3): 229-36.  
[<http://dx.doi.org/10.1046/j.1365-2893.1999.00163.x>] [PMID: 10607235]
- [11] Ying C, Colonno R, De Clercq E, Neyts J. Ribavirin and mycophenolic acid markedly potentiate the anti-hepatitis B virus activity of entecavir. *Antiviral Res* 2007; 73(3): 192-6.  
[<http://dx.doi.org/10.1016/j.antiviral.2006.10.003>] [PMID: 17098296]
- [12] Wong GLH, Wong VWS, Hui VWK, *et al.* Hepatitis flare during immunotherapy in patients with current or past hepatitis B virus infection. *Am J Gastroenterol* 2021; 116(6): 1274-83.  
[<http://dx.doi.org/10.14309/ajg.0000000000001142>] [PMID: 33560651]
- [13] You H, Peng L, Zhao J, *et al.* Clinical characteristics of systemic lupus erythematosus with cirrhosis. *J Immunol Res* 2020; 2020: 1-7.  
[<http://dx.doi.org/10.1155/2020/2156762>] [PMID: 32537465]
- [14] Yetginoglu O, Atas DB, Yilmaz Y, *et al.* Fibroscan detection of fatty liver and liver fibrosis in patients with systemic lupus erythematosus. *Lupus* 2022; 31(6): 723-9.  
[<http://dx.doi.org/10.1177/09612033221094708>] [PMID: 35403493]
- [15] Huang D, Aghdassi E, Su J, *et al.* Prevalence and risk factors for liver biochemical abnormalities in Canadian patients with systemic lupus erythematosus. *J Rheumatol* 2012; 39(2): 254-61.  
[<http://dx.doi.org/10.3899/jrheum.110310>] [PMID: 22174205]
- [16] Gibson T, Myers AR. Subclinical liver disease in systemic lupus erythematosus. *J Rheumatol* 1981; 8(5): 752-9.  
[PMID: 7310775]
- [17] Zheng RH, Wang JH, Wang SB, Chen J, Guan WM, Chen MH. Clinical and immunopathological features of patients with lupus hepatitis. *Chin Med J* 2013; 126(2): 260-6.  
[PMID: 23324274]
- [18] Mori S, Fujiyama S. Hepatitis B virus reactivation associated with antirheumatic therapy: Risk and prophylaxis recommendations. *World J Gastroenterol* 2015; 21(36): 10274-89.  
[<http://dx.doi.org/10.3748/wjg.v21.i36.10274>] [PMID: 26420955]
- [19] Lim DH, Kim YG, Lee D, *et al.* Immunoglobulin G levels as a prognostic factor for autoimmune hepatitis combined with systemic lupus erythematosus. *Arthritis Care Res* 2016; 68(7): 995-1002.  
[<http://dx.doi.org/10.1002/acr.22800>] [PMID: 27338104]
- [20] Piga M, Vacca A, Porru G, Cauli A, Mathieu A. Liver involvement in systemic lupus erythematosus: Incidence, clinical course and outcome of lupus hepatitis. *Clin Exp Rheumatol* 2010; 28(4): 504-10.  
[PMID: 20609296]
- [21] Matsumoto T, Kobayashi S, Shimizu H, *et al.* The liver in collagen diseases: Pathologic study of 160 cases with particular reference to hepatic arteritis, primary biliary cirrhosis, autoimmune hepatitis and nodular regenerative hyperplasia of the liver. *Liver* 2000; 20(5): 366-73.  
[<http://dx.doi.org/10.1034/j.1600-0676.2000.020005366.x>] [PMID: 11092254]
- [22] Matsumoto T, Yoshimine T, Shimouchi K, *et al.* The liver in systemic lupus erythematosus: Pathologic analysis of 52 cases and review of Japanese autopsy registry data. *Hum Pathol* 1992; 23(10): 1151-8.  
[[http://dx.doi.org/10.1016/0046-8177\(92\)90033-Y](http://dx.doi.org/10.1016/0046-8177(92)90033-Y)] [PMID: 1398643]
- [23] Zuppa AA, Riccardi R, Frezza S, *et al.* Neonatal lupus: Follow-up in infants with anti -SSA/Ro antibodies and review of the literature. *Autoimmun Rev* 2017; 16(4): 427-32.  
[<http://dx.doi.org/10.1016/j.autrev.2017.02.010>] [PMID: 28212920]
- [24] Manderson AP, Botto M, Walport MJ. The role of complement in the development of systemic lupus erythematosus. *Annu Rev Immunol* 2004; 22(1): 431-56.  
[<http://dx.doi.org/10.1146/annurev.immunol.22.012703.104549>] [PMID: 15032584]
- [25] Vaiphei K, Bhatia A, Sinha S. Liver pathology in collagen vascular disorders highlighting the vascular changes within portal tracts. *Indian J Pathol Microbiol* 2011; 54(1): 25-31.  
[<http://dx.doi.org/10.4103/0377-4929.77319>] [PMID: 21393872]
- [26] Arnett FC, Reichlin M. Lupus hepatitis: An under-recognized disease feature associated with autoantibodies to ribosomal P. *Am J Med* 1995; 99(5): 465-72.  
[[http://dx.doi.org/10.1016/S0002-9343\(99\)80221-6](http://dx.doi.org/10.1016/S0002-9343(99)80221-6)] [PMID: 7485202]
- [27] Carmona-Fernandes D, Santos MJ, Canhão H, Fonseca JE. Anti-ribosomal P protein IgG autoantibodies in patients with systemic lupus erythematosus: Diagnostic performance and clinical profile. *BMC Med* 2013; 11(1): 98.  
[<http://dx.doi.org/10.1186/1741-7015-11-98>] [PMID: 23557114]
- [28] Bonfá E, Golombek SJ, Kaufman LD, *et al.* Association between lupus psychosis and anti-ribosomal P protein antibodies. *N Engl J Med* 1987; 317(5): 265-71.  
[<http://dx.doi.org/10.1056/NEJM19870703170503>] [PMID: 3496538]
- [29] Mahler M, Kessenbrock K, Szmyrka M, *et al.* International multicenter evaluation of autoantibodies to ribosomal P proteins. *Clin Vaccine Immunol* 2006; 13(1): 77-83.  
[<http://dx.doi.org/10.1128/CVI.13.1.77-83.2006>] [PMID: 16426003]
- [30] Miller MH, Urowitz MB, Gladman DD, Blendis LM. The liver in systemic lupus erythematosus. *Q J Med* 1984; 53(211): 401-9.  
[PMID: 6484120]
- [31] Takahashi A, Abe K, Saito R, *et al.* Liver dysfunction in patients with systemic lupus erythematosus. *Intern Med* 2013; 52(13): 1461-5.  
[<http://dx.doi.org/10.2169/internalmedicine.52.9458>] [PMID: 23812192]
- [32] Tagawa Y, Saito T, Takada K, Kawahata K, Kohsaka H. Successful treatment of severe refractory lupus hepatitis with mycophenolate mofetil. *Lupus* 2016; 25(5): 543-6.  
[<http://dx.doi.org/10.1177/0961203315625118>] [PMID: 26762472]